

Therapeutic Effect of Intravitreal of Ocular Complications Using Single Dose of Bevacizumab Injection for Patients with Proliferative Diabetic Retinopathy

Saif Abass AL-Shamarti¹, Mustafa Tawfik Al-Rubaie², Al-Timmemi H³,
Dhurgham H⁴

College of Medicine, University of Qadisiyah¹, College of Medicine, University of Babylon², College of Veterinary Medicine, Baghdad University³, College of Veterinary Medicine, Kufa University⁴

Correspondence address: dr.saifophthalmology@hotmail.com

Abstract

The aim of this study was to evaluate the therapeutic effect of ocular complications using intravitreal bevacizumab (Avastin) bevacizumab injection for patients with proliferative diabetic retinopathy. The study was conducted in an Ibsar center in Al-Najaf- Iraq in 2014 on of 100 patients (one eye from each patient) participated in the study, the age was ranging from 50 years old to 63 years old and followed up for 6 months. The results of this study that treated by Bevacizumab (avastin) injection showed 79% (79 out of 100 effects eyes) recovered improving without complication according to the interval examinations on next day, one week later and then monthly for six months after operation. While, there 10 patients were showed with sub conjunctival hemorrhage which resolved spontaneously within a week, two 2 patients had post-operative endophthalmitis that responded well to intravitreal antibiotic injection of ceftazidime and vancomycin. In conclusion, the treatment effected eyes of patients with proliferative diabetic retinopathy using of Intravitreal of Avastin injection is effective in rapidly controlling neovascularization and generally safe with minimal risks under good attention regarding sterilization, technique and surgical procedure with accurate post operative following up.

Keywords: Intravitreal Ocular, Bevacizumab, Diabetic Retinopathy, Single dose

{**Citation:** Saif Abass AL-Shamarti, Mustafa Tawfik Al-Rubaie, Al-Timmemi H, Dhurgham H. Therapeutic effect of intravitreal of ocular complications using single dose of bevacizumab injection for patients with proliferative diabetic retinopathy. American Journal of Research Communication, 2015, 3(7): 31-36} www.usa-journals.com, ISSN: 2325-4076.

Introduction

Diabetic retinopathy is predominantly if microangiopathy in which small blood vessels are particularly vulnerable to damage by direct hyperglycemic effects on retinal cells (Fung et al., 2006). Neovascularization is caused by capillary of non-perfusion which leads to retinal hypoxia might progress to neovascularization extending preretinal and intraretinal. Intraretinal microvascular abnormalities (IRMA) are shunts that run within the retina from arterioles to venules. New vessels growth is thought to be caused by imbalance between the elaboration of angiogenic and antiangiogenic factors, putatively in an attempt to revascularize hypoxic retina (Ferrara et al., 2003; Fung et al., 2006; Brad, 2015).

Many angiogenic stimulators have been identified, vascular endothelial growth factor (VEGF) especially VEGF-A appears to be of particular importance, platelet derived growth factor and hepatocyte growth factor (Hoeben et al., 2004). Several endogenous inhibitors of angiogenesis have also been reported such as endostatin, angiostatin and pigment epithelium derived factor (Campochiaro and Hackett, 2003), it has been hypothesized that a key determinant of the activity of retinopathy is the net balance between VEGF and endostatin. The principle of anti VEGF is to prevent the VEGF-A form of the cytokine interacting with the relevant receptors on the endothelial cells surface and reverse neovascularization (Cuenca et al., 2014). Bevacizumab (avastin) is a complete antibody and cheaper in comparison to other anti VEGF, which is associated with fewer systemic side effects with long duration of action, the dose of bevacizumab (avastin) is usually 1.25mg/0.05ml or 2.5mg/0.1ml (Ventrice et al., 2013). However, the aim of this study was to evaluate the therapeutic effect of ocular complications using intravitreal bevacizumab (Avastin) bevacizumab injection for patients with proliferative diabetic retinopathy

Materials and Methods

The study was conducted in an Ibsar ophthalmic center in Al-Najaf- Iraq in 2014 on 100 patients participated (one eye) in the study, the age was ranging from 50 years old to 63 years old and followed up for 6 months where all of them having proliferative diabetic retinopathy. All the patients given preoperative medications included Moxifloxacin eye drop (vigamox) each three hours and Ciprofloxacin tablet 750 mg once a day for three days preoperatively. Single dose of Avastin 0.05ml (1.25 mg)

injected intravitreally into 3.5 to 4mm from the limbus in the superotemporal aspect, the injection applied into the patients in the operative theater, after putting a sterile drape and sterile speculum. The patient was instructed to look up and nasally in order to give the injection using a needle typically insulin syringe (30 gauge) following the injection of vigamox eye drop was installed in the conjunctival sac.

Results

The results of this study on patients' eye that treated by Bevacizumab (avastin) injection showed recovery improving according to the interval examinations on next day, one week later and then monthly for six months after operation. However, showed 79% (79 out of 100 effects eyes) that treated with Bevacizumab (avastin) after operation showed completely recovery without complication. While, there 10 patients showed with sub conjunctival hemorrhage which resolved spontaneously within a week, two 2 patients had post-operative endophthalmitis that responded well to intravitreal antibiotic injection of ceftazidime and vancomycin. Three patients showed slight increase in their intra ocular pressure (IOP) about 25 mmHg that gradually decrease within five days of treatment. Five patients complain of post operative ocular pain that responded well to Panadol extra tablets. 1X3 and only one patient complain from sterile uveitis which responded well to topical steroids (Figure 1).

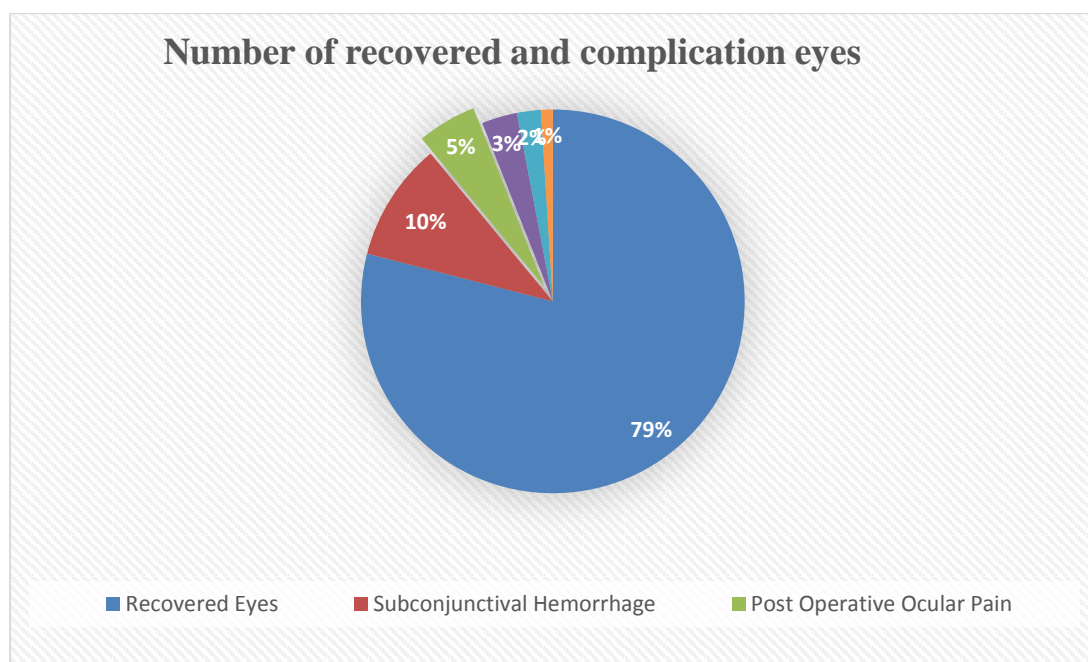


Figure 1: Showing the number of recovered and had complications eyes.

Discussion

The results of this study on effected patients' eyes with proliferative diabetic retinopathy that treated by Bevacizumab (avastin) injection showed 79% of operated eyes were recovery improving without complications. This study was in agreement with previous study (Costagliola et al., 2008) reported that the more that 80% of treated effected eyes using bevacizumab got recovery within the time after the operation.

In this study, the avastin is used and it is remain the most commonly used because of its price safety and less systemic side effects. However, we concentrated on ocular post operative complications rather than the systemic side effects, therefore, the results showed the most complications of treated eyes after the operation were simple and self-limiting although two cases of endophthalmitis occurred which is an acceptable risk and explained to all patients before the injection, these two patients responded well to intravitreal of antibiotics treatment. Another study showed that bevacizumab is the most cost-effective drugs and therefore widely used in diabetic macular edema (DME)(Kriechbaum et al., 2014).

From this study, the opinion of avastin regarding its price and less systemic side effects and availability in our country considered the corner stone in proliferative diabetic retinopathy if compared with other Anti VEGF, however pervious study by Noma et al. (2005) confirmed that the anti-vascular endothelial growth factor (VEGF) therapy for the treatment of ocular diseases also appears promising for diabetic retinopathy (DRP), where the VEGF levels had ability to active neovascularization and macular edema.

There were no statistically significant differences between the two dose groups with regard to the number of injections and anatomical and functional outcomes. Multiple injections are needed in a large number of eyes for continued control of macular edema and preservation of visual acuity in the short term. Longer studies are needed to determine what role if any intravitreal injection of bevacizumab may play in the long-term treatment of this condition (Wu et al., 2008). In conclusion, the treatment effected eyes of patients with proliferative diabetic retinopathy using of Intravitreal of Avastin injection is effective in rapidly controlling neovascularization and generally safe with minimal risks under good attention regarding sterilization, technique and surgical procedure with accurate post-operative following up.

References

- Brad Bowling (2015). Kanski's Clinical Ophthalmology: A Systematic Approach, Elsevier Health Sciences Eighth edition. Imprint: Saunders, ISBN: 978-0-7020-5572-0.
- Campochiaro Peter Anthony and Hackett Sean Francis (2003). Ocular neovascularization: a valuable model system *Oncogene* 22, 6537–6548.
- Costagliola C, Cipollone U, Rinaldi M, della Corte M, Semeraro F, Romano MR. (2008). Intravitreal bevacizumab (Avastin®) injection for neovascular glaucoma: a survey on 23 cases throughout 12-month follow-up. *British Journal of Clinical Pharmacology*, 66(5):667-673.
- Cuenca Nicolas, Laura Fernandez- anchez, Laura Campello ,Victoria Maneu, Pedro De la Villa, Pedro Lax, Isabel Pinilla (2014). Cellular responses following retinal injuries and therapeutic approaches for neurodegenerative diseases. *Progress in Retinal and Eye Research* 43 17-75.
- Ferrara N, Gerber HP, LeCouter J. (2003). The biology of VEGF and its receptors. *Nat Med*; 9: 669-76.
- Fung AE, Rosenfeld PJ, Reichel E. (2006). The International intravitreal Bevacizumab Safety Survey. *Br J Ophthalmol*, 90: 1344-9.
- Hoeben Ann, Bart Landuyt, Martin S. Highley, Hans Wildiers, Allan T. Van Oosterom, and Ernst A. De Bruijn (2004). Vascular Endothelial Growth Factor and Angiogenesis. *Pharmacological Reviews*, 56. 4549-580.
- Kriechbaum K, Prager S, Mylonas G, Scholda C, Rainer G, Funk MM. (2014). Intravitreal bevacizumab (Avastin) versus triamcinolone (Volon A) for treatment of diabetic macular edema: one-year results. *Eye*, 28(1), 9–16.
- Noma H, Funatsu H, Yamasaki M, Tsukamoto H, Mimura T, Sone T, Jian K, Sakamoto I, Nakano K, Yamashita H, Minamoto A, Mishima HK. (2005). Pathogenesis of macular edema with branch retinal vein occlusion and intraocular levels of vascular endothelial growth factor and interleukin-6. *Am J Ophthalmol*, 140(2): 256-261.
- Ventrice Pasquale, Christian Leporini, Jose' Francisco Aloe, Ettore Greco, Giacomo Leuzzi, Giuseppina Marrazzo, Giovanni Battista Scordia, Donatella Bruzzichesi, Varano Nicola, Vincenzo Scordia (2013).___Anti-vascular

endothelial growth factor drugs safety and efficacy in ophthalmic diseases. J Pharmacol Pharmacother, 4(Suppl1): S38–S42.

Wu L, Arevalo JF, Roca JA, Maia M, Berrocal MH, Rodriguez FJ, Evans T, Costa RA, Cardillo J; Pan-American (2008). Comparison of two doses of intravitreal bevacizumab (Avastin) for treatment of macular edema secondary to branch retinal vein occlusion: results from the Pan-American Collaborative Retina Study Group at 6 months of follow-up. Retina, 28(2):212-9.